

# Some Observations upon the Development of the Teeth of *Physeter macrocephalus*.

By

Frank E. Beddard, D.Sc., M.A., F.R.S.

---

With 13 Text-figures.

---

On the following pages I describe the nature of the tooth rudiments in the very young embryo of *Physeter macrocephalus*, whose general external characters I have already commented upon and figured (Beddard, 1). Since the material upon which I have worked is, so far as I am aware, a unique specimen only  $4\frac{1}{2}$  inches long, I am particularly grateful to the Curator of the Durban Museum (Mr. E. C. Chubb) for placing it in my hands and to the authorities of the Museum of the Royal College of Surgeons of England for allowing their highly skilled assistant, Mr. Steward, to prepare a series of sections for study.

## GENERAL CHARACTERS OF TEETH IN FOETAL SPERM WHALE.

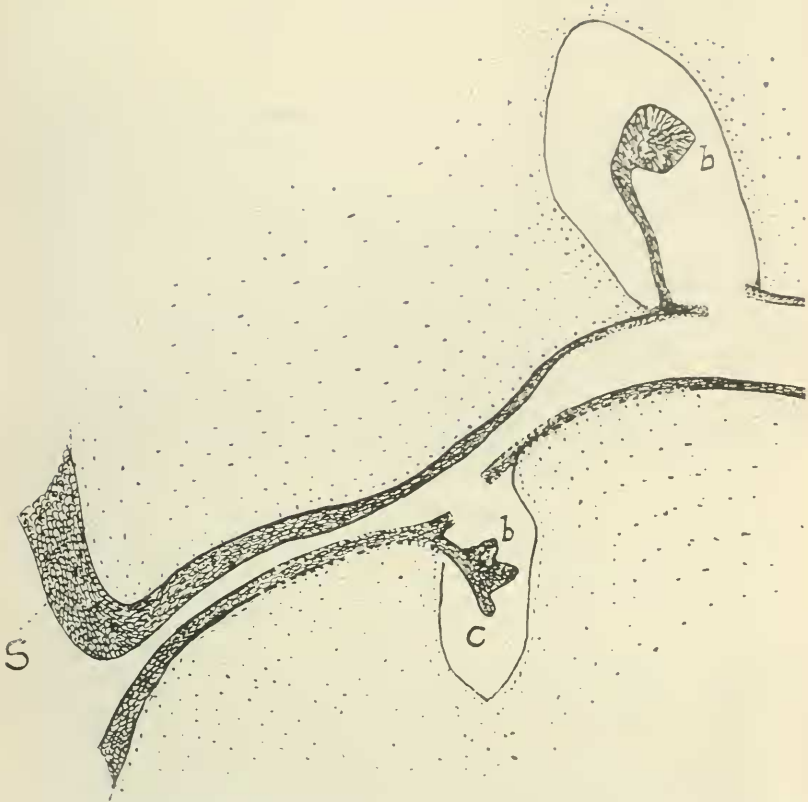
Although the teeth of the adult sperm whale, of both lower and upper jaws, are well known (Ritchie and Edwards, 5), the development of the teeth in this cetacean is described in only one memoir (Pouchet and Beauregard, 4), so far as I am aware. This memoir contains a description of the teeth in an embryo of 30 cm. : those of both jaws are described and figured. This embryo, it will be noted, is about twice the size of that dealt with in the present communication. There is not, however, as it would appear, a great deal of difference in the condition of development of the teeth : hence I have not very much to add to the description of Messrs. Pouchet and Beauregard. Apart, however, from such new facts as I am

able to set forth here, certain peculiarities in the growth of the teeth of *Physeter macrocephalus* are worth confirmation, though I doubt whether I am able to settle definitely the question of the homologies of the teeth of the adult, whether—that is to say—they belong to the milk or permanent dentition. The former view of the odontocyte dentition seems to be the one generally held; but by others the question is considered to be still open. It should be added, however, that these views are not at all based upon a consideration of the facts described by Pouchet and Beaugard, whose memoir has been largely overlooked. This is a further reason for again directing the attention of zoologists to this subject.

I may commence by directing attention to a matter not illustrated in the figures of the teeth published by Messrs. Pouchet and Beaugard; this is the position of the teeth of the upper and lower jaw with reference to each other. It will be seen by an inspection of Text-fig. 1 that the teeth of the upper jaw are divided from each other by a space that is less than the space dividing the two teeth rows of the lower jaw—that is to say, the upper teeth are distinctly within the lower teeth. Furthermore, the upper teeth are quite vertical in position, and at right angles with the longitudinal axis of the head, while the two rows of teeth in the lower jaw are at an angle to each other, and to the same axis of the head. Thus the teeth of the lower jaw look outwards as well as upwards, while those of the upper jaw are directed downwards only. This state of affairs is more marked in the anterior region of the lower jaw. It is due to the varying contour of the lower jaw, which anteriorly is more rounded while posteriorly the upper surface is straighter. Thus the teeth are, so to speak, carried on to what is largely the lateral surface.

This figure also shows a character which is to be seen more in detail in subsequent illustrations of the teeth of this foetus. The cavity in which the tooth rudiments lie is not at all invaded by the upgrowth from below forming the dental papilla, which is only represented in this stage by a thickening of the mesodermic tissue shown by a closer approximation of the nuclei

TEXT-FIG. 1.



In this and the ensuing figures the following general statement holds good of all, and need not be repeated. The figures are of sections cut deliberately thick, the diameter being  $25\ \mu$  (i. e.  $\frac{1}{40}$  mm.). The direction of all the sections is transverse to the long axis of the head. Where necessary for explanation, the sign \* is on the lingual side. The following lettering is employed :

*a*, rudiment of milk tooth. *b*, rudiment of permanent tooth. *c*, residual lamina. *d.p.*, rudiment of dentine papilla. *E.*, Epithelium of mouth cavity which gives origin to dental lamina. *S*, side of head. *U.J.*, upper jaw. *L.J.*, lower jaw.

Fig. 1 represents a portion of the upper and lower jaw to show the position of the tooth germs of these two jaws in relation to each other. The tooth of the lower jaw is seen to lie outside of that of the upper jaw.

of this tissue. The peculiarly large extent of this cavity, which will be dealt with immediately, is possibly to be looked upon as a preparation for the subsequent growth of the dental papilla.

The ingrowths of the epidermis to form the enamel organ, instead of lying within—and firmly embedded therein—the mesoderm tissue underlying the epidermis, depend freely into a spacious cavity just referred to, which forms the tooth follicle. Pouchet and Beauregard figure extensive spaces surrounding these ingrowths, but not to so large an extent as I have found in the young embryos examined by myself. In the lower jaw of my foetus the space invariably commenced immediately below the epidermis; but in the upper jaw there was frequently a layer of mesoderm immediately underlying the epidermis and perforated by the ingrowth. In other mammals spaces are apt to occur in the same way. The cavities are so large that they are only moulded in the roughest way to the enamel ingrowth; it is to be remarked, however, that—in the upper jaw at any rate—the labial outgrowths (see Text-figs. 9–12) of the dental lamina, which will be dealt with later, lie in one or two diverticula of this cavity, and in the same way free within it; they are not closely adpressed to its walls. I imagine that this state of affairs is not altogether natural, but is due to reagents and consequent shrinkage. I have no means, however, of ascertaining whether any part of this cavity is normal. In any case the practical result is that both in upper and in lower jaw a canal is formed which is quite continuous from one end to the other of both jaws. This cavity gradually narrows at the extreme end of the series of teeth and finally ceases to exist close beneath the epidermis. It is possible that it is associated with the groove which in this and other cetaceans lodges the teeth in the adult animal.

It is, furthermore, possible that something of the same kind led to the erroneous views upon the development of the teeth expressed by Goodsir, whose figures persisted until quite lately in text-books such as 'Quain's Anatomy'.<sup>1</sup> Here the

<sup>1</sup> 8th ed., vol. ii. 1876, p. 315, fig. 214, 3 and 4.

growing tooth is represented as the dental papilla only, growing upwards into a cavity.

A rough survey of the series of sections, one of which is shown in Text-fig. 1, shows also that there is apt to be considerable difference in size between some of the tooth cavities of the upper jaw and those of the lower. This is not always the case; but posteriorly (i. e. nearer to the condyle of the jaw) the follicles of the upper jaw teeth are deeper than those of the lower jaw, even twice as deep, in that and other regions. This is correlated with a greater length of the dental lamina, which will now be described.

It seems to be a general rule—so general that Sir Charles Tomes (6) makes his diagrams of the developing teeth conform to it—that the dental lamina is oblique in direction, running indeed at times almost parallel with the oesophageal epithelium, of which it is a downgrowth. In *Physeter*, as the figures of Pouchet and Beaugard indeed show, this lamina is absolutely at right angles to the oesophageal epithelium. This will be apparent from an examination of Text-figs. 3 and 4, &c., annexed hereto. The origin of the lamina shows no points of particular interest. It arises from the malpighian stratum, at both sides of an ingrowth of the superficial layer of cells which thus forms its core.

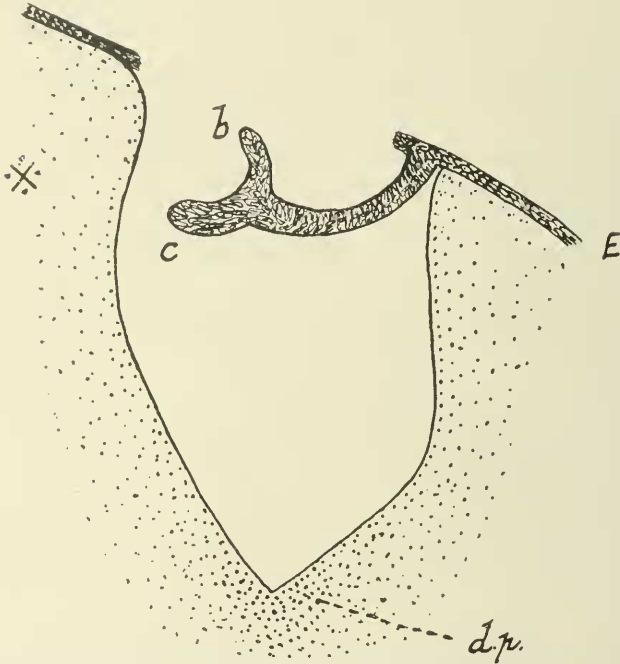
The histological condition of the material was good enough to show the difference between the central core of the lamina and the often cubical layer of epidermis which surrounds it externally. I do not, however, attempt any special description of the various cells, as they do not seem to present any features of disagreement with those of the developing teeth in other mammals.

#### TEETH OF THE LOWER JAW.

My examination of the teeth of the lower jaw was hindered by the condition of the sections of the anterior region of these jaw rami. The tooth follicles upon which I have already commented were often entirely empty of contents, the jaws being here obviously more exposed to external injury. I have, how-

ever, no other reason to doubt that the teeth rudiments were like<sup>1</sup> those situated more posteriorly, which presented very few such lacunae. Still, in attempting general statements concern-

TEXT-FIG. 2.



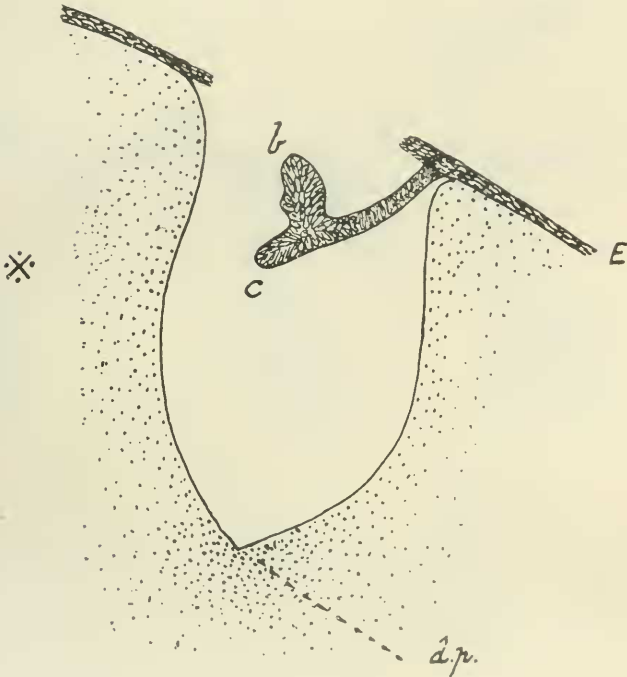
Tooth of lower jaw. This figure and the two following are a nearly continuous series, one section only lying between each section figured. The mouth epithelium is seen to be ruptured owing to the swelling of the tooth follicle, and the dental lamina with its tooth germs to be dislocated towards the lingual side. The dental papilla is no more than a closer agglomeration of the mesoderm cells at the base of the tooth follicle.

<sup>1</sup> I could only find one series of teeth in the anterior part of the jaw and these were quite early. The only difference from those which are described more in detail below is that the actual tooth germ is longer and more parallel with the residual lamina, and that the latter tends to disappear between successive tooth germs; there is thus an approximation in structure to the teeth of the upper jaw. But the dental lamina remains very short as in the posterior teeth of this jaw. These anterior teeth are evidently more advanced in development.

ing the mandibular teeth the defective condition here referred to must be borne in mind. I shall have, for example, to indicate actual structural differences between the teeth of the mandibles and those of the maxillae and premaxillae.

These teeth are readily comparable at first sight with the

TEXT-FIG. 3.

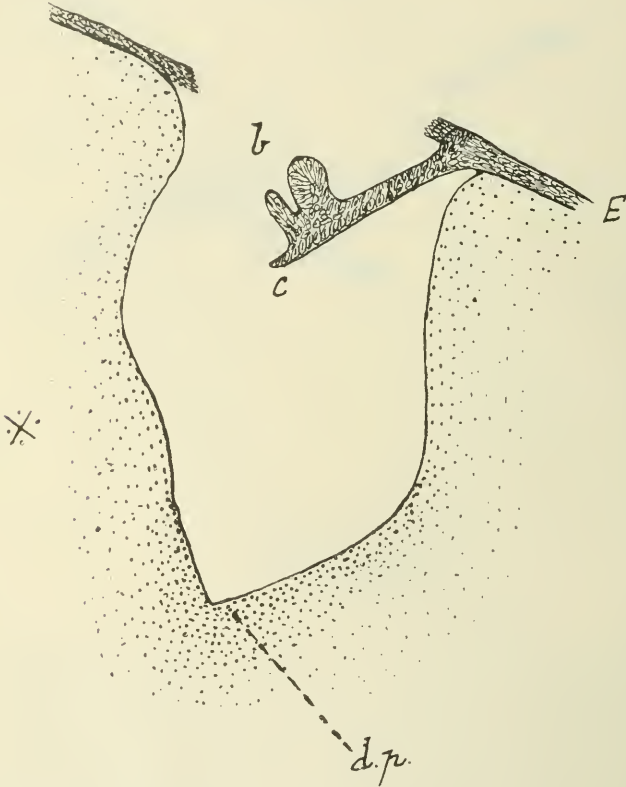


As Text-fig. 2, but the rudiment of permanent tooth is larger.

teeth of other mammals in a corresponding stage of development. The tooth rudiment shown (Text-fig. 4) as a bell-shaped swelling seems to be clear; and beyond this, i. e. distally from the place of origin of the dental lamina, is a prolongation which would seem to correspond to the residual lamina of other teeth. They all presented more or less the appearance shown in Text-figs. 2, 3, 4. The entire organ developed from the enamel germ often lay closely adpressed to one side of the

copious tooth follicle, but in other cases it lay more in the middle of that follicle removed from its walls. The growing tooth was small compared with those of the upper jaw, which will be dealt with immediately. Each was distinctly marked into three

TEXT-FIG. 4.



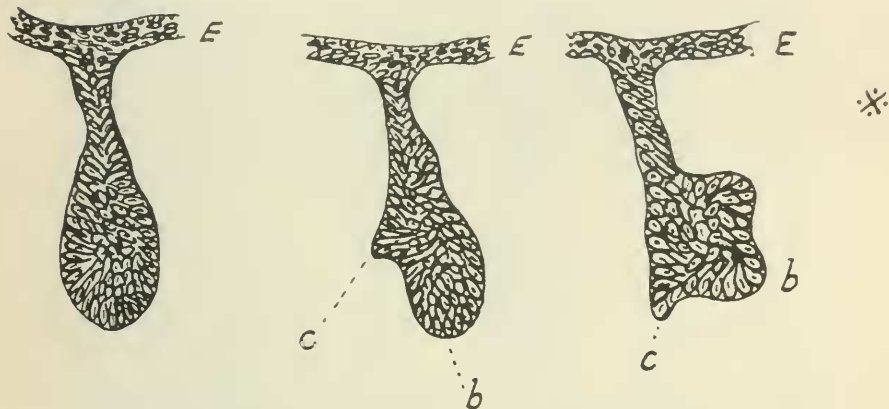
As in two previous sections; the rudiment of the permanent tooth has acquired its full size.

regions, which are very plain—as is shown in the figures already referred to. The tooth itself lies to the lingual side of the ingrowth, and at its middle or thereabouts is rather bell-shaped, or at least divided into two lobes; these look inwards and not downwards. The stalk of which this is an outgrowth, i. e. the



dental lamina is straight and quite at right angles to the oesophageal epithelium. Beyond the origin of the tooth rudiments, as will be seen in the figures, it is continued onwards in the same straight line as the dental lamina, and it is this region which I have termed above the residual lamina. In neighbouring sections to that represented in Text-fig. 4 (see Text-figs. 2, 3) the dental and residual laminae show no differences, but the actual tooth germ is more slender. But

TEXT-FIG. 5.



Three sections, near to each other, from the condylar end of the lower jaw, representing three stages in the growth of the tooth germ. The left-hand figure represents the initial stage, in which the entire tooth germ is a mere swelling of the dental lamina. Later (the middle figure) the residual lamina becomes differentiated; and the third section shows the complete differentiation of the rudiment of the permanent tooth.

it does not appear ever to vanish between successive teeth, but to be continued as a lamina, the actual tooth germ being local thickenings of this. The residual lamina undergoes no change in the intervals between the teeth, but it may at times terminate in a more club-shaped or at least slightly swollen extremity than in other places. At the very beginning of the series of tooth rudiments of the lower jaw—at the end nearest to the condyles—the rudiment consists (see Text-fig. 5) of a swollen extremity supported by a short stalk. This resembles

the first of the series of the upper jaw, which will now be described. It will be noted, therefore, that here, as in the upper jaw, the tooth series develops from behind forwards.

#### TEETH OF THE UPPER JAW.

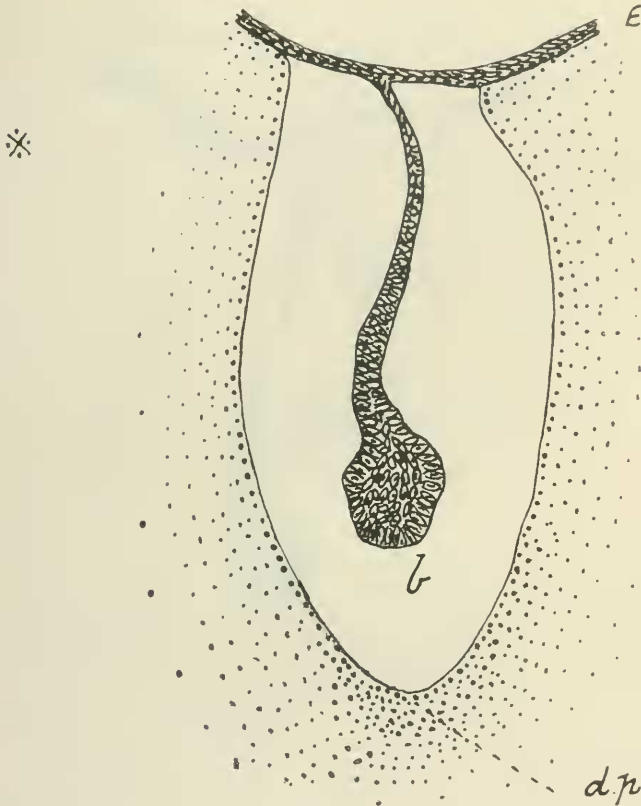
In the case of the upper jaw I was also able to trace the dental lamina to the very end, close to the condyle. It begins here as a much shorter fold than it becomes farther forward. The fold at the very first is more or less oval in transverse section, and later appears club-shaped. It becomes separated in fact into the oval free extremity and a much more slender stalk. The expanded free edge of the dental lamina may be traced forwards into the series of rudimentary teeth. The only change at first in this region of the dental lamina is the increase in size, at intervals and for the distance of a few sections, of the expanded free extremity. Nevertheless, it is particularly to be noted that where there are no signs of tooth formation the ending of the lamina is still swollen. It has been asserted and denied<sup>1</sup> that a swollen extremity of the dental lamina argues the actual presence of a rudimentary tooth germ. It would seem likely in the present case that the region of the jaw which we are now considering will ultimately be furnished with teeth. But I have no positive facts to fix the validity of this decision. And, moreover, in view of the apparent agreement in age of all the undoubted tooth germs in both jaws, it might be argued with equal force that the terminal region is not to be invaded by teeth. In this event the swelling of the edge of the dental lamina will be an argument in support of those who see in a terminal swelling no actual prophecy of teeth in the same situation, however rudimentary those teeth may be.

The accompanying figure (Text-fig. 6) shows an early tooth follicle with the dental lamina therein and that it ends in a slight swelling. It will be noticed that the terminal swelling is continued in the same straight line as the rest of the dental lamina. The next figure (Text-fig. 7) shows a section some way farther on towards the symphysis of the jaws; and in this a slight

<sup>1</sup> See, for a brief summary of these views, Tomes (6, p. 357).

alteration is to be noted. The terminal swelling—not particularly strongly marked and so far like the first of this group of sections which has just been described—is not in the same

TEXT-FIG. 6.

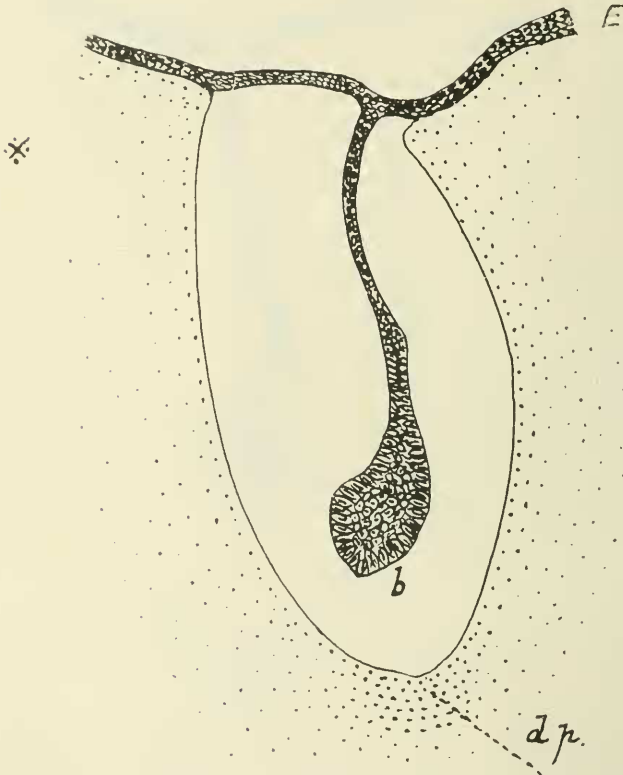


An early stage in the development of a tooth of the upper jaw. This, with Text-figs. 7, 8, is to be compared with Text-fig. 5, which represents three more or less equivalent stages in the development of the lower jaw teeth. The much greater length of the dental lamina will be noted.

straight line with the remainder of the dental lamina. It is distinctly turned lingually at almost, or in some sections quite at, right angles to the rest of the lamina. A further stage of

development of the tooth series of the upper jaw is to be seen in Text-fig. 8, which is the third of the present series. Here we have a dental lamina with terminal tooth swelling shaped—as in the last—much as a tobacco pipe, the ‘bowl’ being

TEXT-FIG. 7.

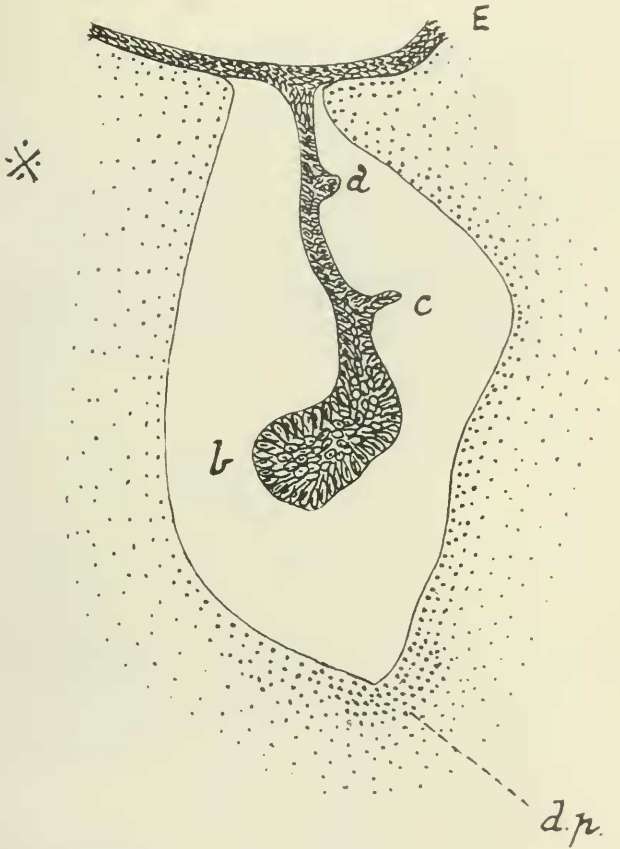


A stage farther than that represented in Text-fig. 6. The tooth rudiment, instead of being a straight continuation of the dental lamina, is slightly bent to lingual side.

turned inwards (lingually) at right angles to the ‘stem’. But there is here a further addition. There are two slight processes upon the labial side which are very short but evidently correspond to the more highly developed processes whose

form and nature will be dealt with presently. We see in these tooth rudiments, early in the series, a commencing of the various characteristics of the fully developed embryonic teeth of this

TEXT-FIG. 8.



A more advanced tooth rudiment. In addition to the more marked bending of the rudiment of the permanent tooth, the commencement of the milk rudiment and the residual lamina is to be seen. In all these three figures the dental papilla is a mere thickening of the mesoderm tissue.

young foetus. It must not, however, be assumed that the labial bud-like outgrowths of the dental lamina are subsequent

in time of origin to the germ of the persisting tooth of the adult which arises from the end of the dental lamina. If this were proved to be the case the homologies of both would need another view than that put forward here. The actual time at which the end of the dental lamina becomes the rudiment of a tooth is hard to decide.

In the memoir of Messrs. Pouchet and Beaugard the authors figure<sup>1</sup> six sections of teeth, of which one only (Text-fig. 6) represents a tooth of the lower jaw. All of the figures are approximately alike, and an inspection of these drawings does not lead to any possibility of distinguishing between the teeth of the two jaws in this cetacean, or at any rate in an embryo of 30 cm. in length. I have already mentioned the fact that I was only able to discover anything that looked definitely like a residual lamina in the teeth of the lower jaw in my younger embryo. Nor do the figures of Pouchet and Beaugard (4) show anything similar beyond all doubt to the projection of enamel tissue which I have figured (see Text-fig. 4) to the labial side of the undoubted tooth rudiment. There is, however, in the former figures a thick process, forming really part of the terminal expansion of the dental lamina, to be seen; but it will be noted that this is on the lingual side. The process does not seem to me to be distinctive enough to set it down as a residual lamina, even without going into the question of its position with regard to the main ingrowth of the dental lamina. And in any case those authors complain of the condition of their specimen, which would render it unwise to do more than call attention to such characters as are obviously not masked by the inferior histological state of this specimen.

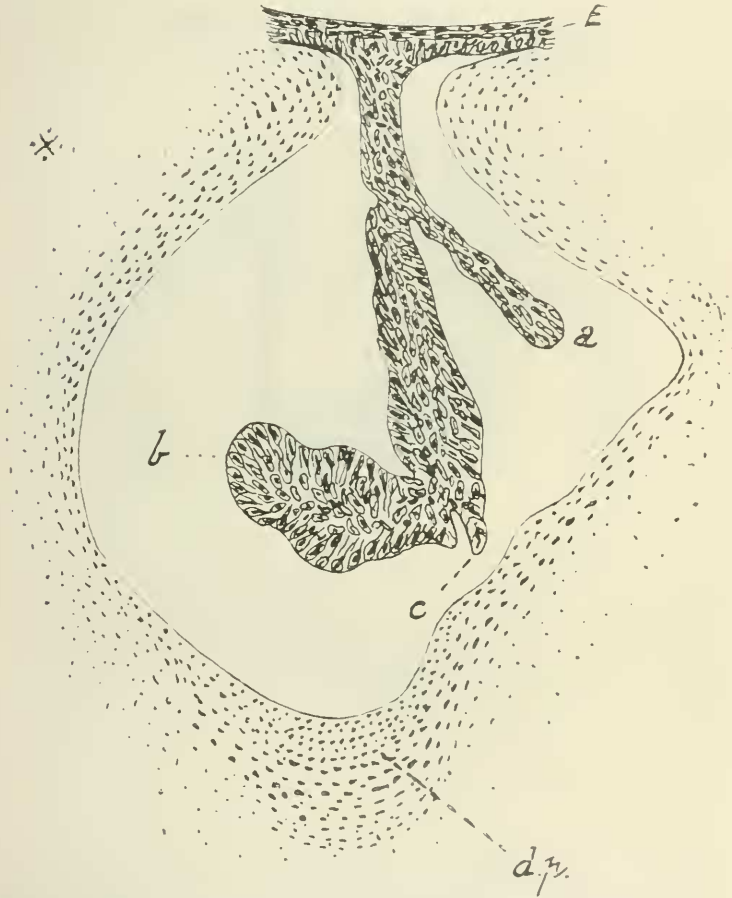
In my younger example there was nothing that could be compared to this residual lamina (if it be so) which is figured by Pouchet and Beaugard.

This, however, may easily be due to the fact that the state

<sup>1</sup> On Pl. vii of the memoir already quoted. I may call attention to the slight confusion in the description of Pls. vii and viii: the former is stated to be of an embryo of 1.30 m., the latter one of 0.30 m. The reverse is obviously the case.

of the tooth development was younger than that of the foetus of Pouchet and Beauregard, and that therefore a definite residual lamina could hardly be expected until a little later.

TEXT-FIG. 9.

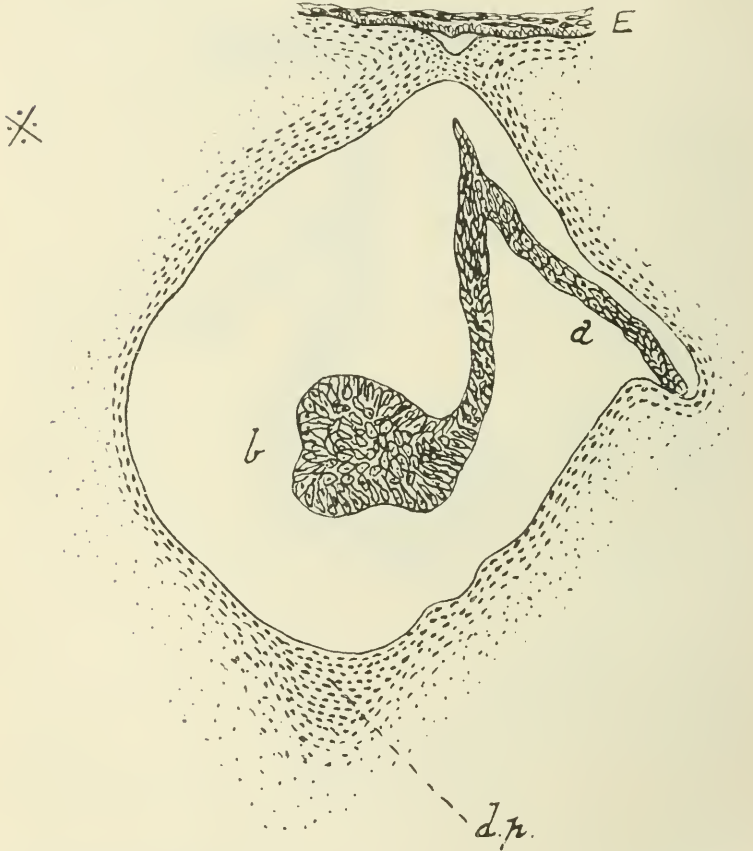

Tooth germ from upper jaw at a more advanced stage of development. The milk rudiment is long and conspicuous, expanded at the extremity.

The teeth of the upper jaw, however, though they show no prolongation of the dental lamina precisely comparable to that

to which attention has just been called, are provided with an outgrowth or outgrowths of which the nature is also difficult to decide. These are figured in Text-figs. 9, 10. They lie

TEXT-FIG. 10.



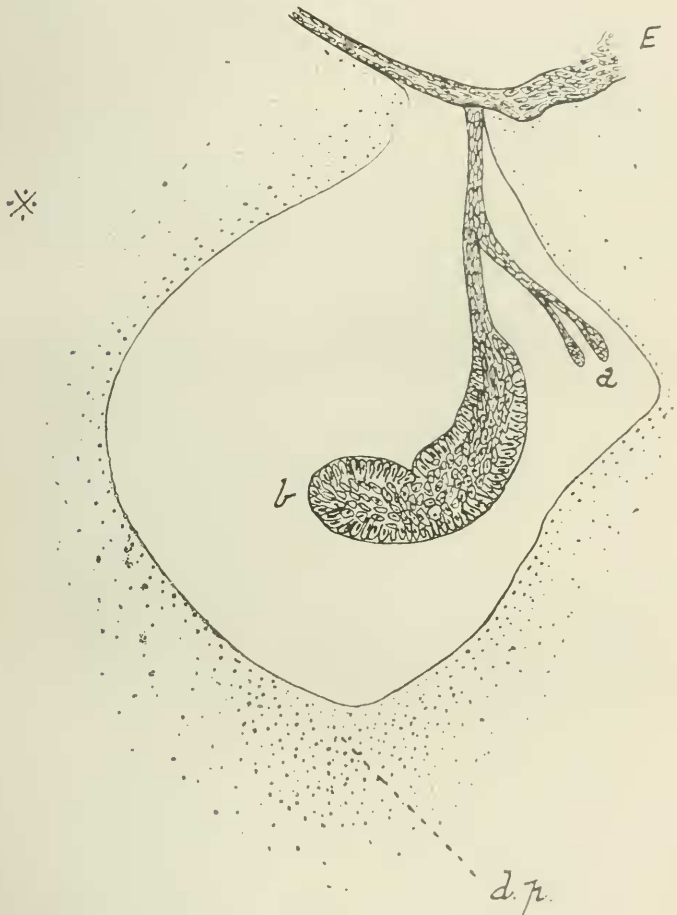The next section but one to that figured in Text-fig. 9. The residual lamina is not to be seen.

in the sections which I have in my possession invariably on the labial side of the dental lamina. There are quite frequently, perhaps always, two of them—or even three, of which two may even arise by a common origin (Text-fig. 11) from the



dental lamina well behind its termination in a tooth germ. These outgrowths end in a swollen termination egg-shaped in

TEXT-FIG. 11.



Another tooth rudiment in the neighbourhood of those represented in Text-figs. 9, 10. It shows the peculiarity of a double milk outgrowth.

outline. The appearances which I have seen, and which are represented in the annexed figures (Text-figs. 9-11), are

obviously like those of the developing teeth of the older foetus described by Pouchet and Beaugard as regards these outgrowths. But there is one important difference which is particularly to be noted. In my foetus the outgrowths are always on the labial side ; but the figures of the two writers just referred to show that these outgrowths may be also on the lingual side, a fact which will have to be borne in mind in considering the nature of these parts of the tooth germs of the cachalot. They figure two sections in which the outgrowths are on the lingual and not on the labial side (4, Pl. vii, figs. 3 and 5). Furthermore, in the older foetus these outgrowths may become, or be accompanied by, a luxuriant crop of similar outgrowths (Pouchet and Beaugard, 4, Pl. vii, fig. 1) on the same side as the single outgrowth or from the oesophageal epithelium (4, Pl. vii, fig. 5). I have seen nothing of the kind in my specimen. The nearest approach to it is the double outgrowth (Text-fig. 11) in my specimen. Finally, I call attention to the fact that in one section represented by Pouchet and Beaugard there are two outgrowths precisely as in several sections of the series from my younger foetus (4, Pl. vii, fig. 4).

I should mention also that in my specimens one of the two outgrowths only, or it may be two where there are two or three, certainly corresponds to the diverticulum or diverticula of the tooth follicle to which I have referred on a previous page. I am not sure whether this is always the first of the series where there are two or three ; for the great development of the cavity prevents an accurate fitting to the enamel organ. It should be noted also that the long ' stalk ' of these lateral outgrowths ending in a swollen extremity reproduces more exactly the form of the stalked tooth germ of which they are an outgrowth than in the case of the older foetus. This will be apparent from a comparison of Text-figs. 9-11 with those of the French authors. What are these outgrowths of the dental lamina ?

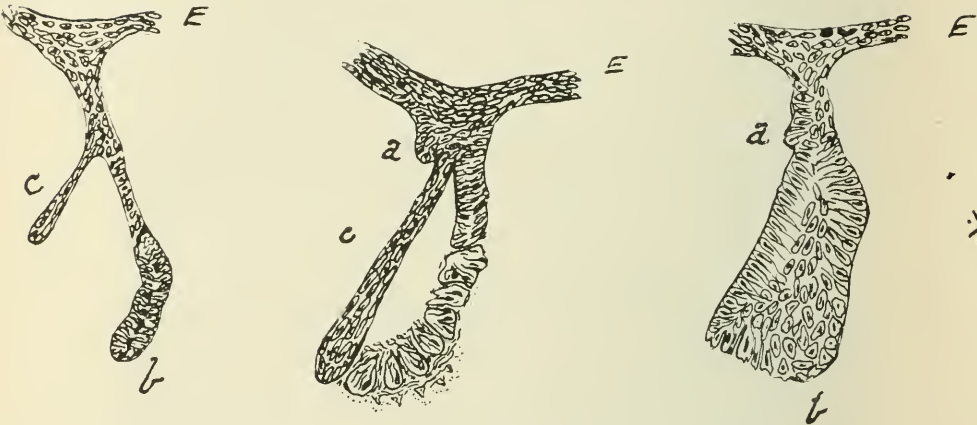
Messrs. Wilson and Hill (7, Pl. ii, figs. 52-4, woodcut figs. 2, 3, pp. 568, 569) figure and describe certain outgrowths from the dental lamina of marsupials (in *Perameles*) on the labial side, and call attention to the reference by the late Mr. Martin

Woodward (9, Pl. xxlvii, figs. 25 *a* and *b*) to similar outgrowths, which (in *Petrogale*) the latter regarded simply as tooth germs. Wilson and Hill, however, find that these outgrowths (in *Perameles* it must be remembered, not *Petrogale*) are really sheets arising from the dental lamina, and not to be confused with dental rudiments. They refer them to the 'labio-alveolar lamina' and trace them back in their origin to the oesophageal epithelium, finding sometimes no connexion at all with the dental lamina. I do not attempt to criticize, and content myself with the briefest account of this view of the labial outgrowths in question. I am convinced, however, that the structures which I describe here in *Physeter macrocephalus* really originate from the dental lamina, and are limited to narrow outgrowths like tooth germs. They are not to be seen throughout a long series of continuous sections; but only in three or four consecutive sections. I have dwelt upon their resemblance to the undoubted tooth germs in this cetacean; indeed, the only difficulty in the way of regarding them as tooth germs might be considered to be their origin from the labial instead of from the lingual side of the dental lamina. But in the first place these rudiments do occasionally originate from the lingual side, as I presume from the figures of Pouchet and Beaugard; and in the second place in a vertically developed dental lamina the actual side of origin seems less important than in an obliquely disposed dental lamina.

Woodward also found no difficulty in referring such outgrowths to a milk dentition, while in the case of the incisors he referred a lingual outgrowth to the permanent series. This position as to the nature of a particular rudimentary tooth is accepted and asserted by Tomes, who writes (6, p. 356): 'we are justified in saying that any additional specialization of the dental lamina which is situated on the lingual side of a formed germ belongs to a later generation of teeth, and conversely that any similar outgrowth of the lamina which lies on the labial side of a formed tooth germ belongs to an antecedent generation.' But it would, as I think, be pushing this

generalization too far to regard the (? same) outgrowths of this embryo of *Physeter* as a rudiment of a milk dentition when they appear on the labial side and of a postpermanent generation when they are processes of the lingual surface of the dental lamina. There are, however, as it appears to me from the facts represented in my sections, and from the literature briefly referred to above, considerable grounds for believing these outgrowths of the dental lamina in *Physeter* to represent

TEXT-FIG. 12.



Three sections at an interval from each other of one section only, nearer to the anterior end of the upper jaw than those sections represented in preceding figures, and therefore at the most complete stage of development shown in the foetus examined. They show certain differences from the more posteriorly situated sections of the upper jaw series. This chiefly affects the relative positions of the milk rudiment (*a*) and the residual lamina (*c*) to each other and to the germ of the permanent tooth (*b*) (assuming that these several outgrowths are correctly identified).

vestiges of a milk dentition which never comes to maturity, and that the permanent teeth of this cetacean are therefore to be looked upon as the equivalent of the permanent dentition of other mammals. This conclusion is not that of Kükenthal (2), who, however, did not (probably was not able to) refer to the memoir of Bouchet and Beauregard owing to nearly simultaneous publication.

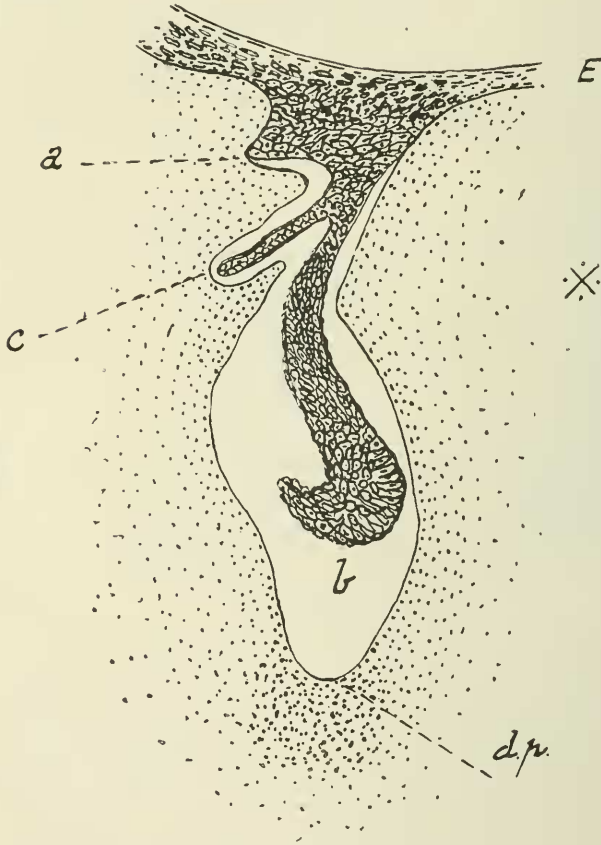
I have in a few cases (Text-fig. 12) found an apparent absence of a second outgrowth of the dental lamina. There is here a specially long single outgrowth which is less like a residual lamina than in other teeth, as may be noted by a comparison with Text-fig. 9. Nevertheless, there are some reasons for regarding this outgrowth as the representative of the residual lamina though the usually present additional outgrowth seems to be absent. I believe, however, that this structure is not absent, but present in the form of a process of epithelium of a somewhat different appearance and origin. Close to the stalk of the dental lamina, and close to its origin from the oesophageal epithelium, is a pyramidal heap of cells which is continuous with the stalk but also arises separately from the oesophageal epithelium. This pyramid has its apex directed upwards, its wider base being continuous with the oesophageal epithelium. It is not large, as I could only find it in one to three continuous sections. I think that this outgrowth may be compared with that which I have described above as existing in most of the teeth of the upper jaw. If this supposition is wrong, I cannot at the moment compare it with anything else, except perhaps as a dwarfed equivalent of the mass of independent outgrowths which Pouchet and Beaugerard have figured as growing from the oesophageal epithelium in the immediate neighbourhood of a tooth germ.

It should be noted (as is shown in Text-fig. 13) that this pyramidal outgrowth is received into an excavation of the mesoderm tissue surrounding the tooth follicle, as are other parts of the developing tooth series. It is not, therefore, to be looked upon as merely an outgrowth of the oesophageal epithelium having no relation to a particular tooth germ.

It is possibly the case that the absence of the basal pyramidal outgrowth of the oesophageal epithelium to which reference has just been made is not always a reality, for in the three consecutive sections in one case (Text-fig. 12) I could find this outgrowth in only one or two sections, and there but small and rather of a rounded than conical form. It may be, therefore, that this structure has been missed or—if present—not

regarded as I regard it (i. e. as a part of a definite tooth outgrowth), in sections such as that which Kükenthal represents of the developing tooth of the Beluga. This latter figure

TEXT-FIG. 13.



Tooth germ belonging, like Text-fig. 12, to those of the anterior part of the upper jaw, but situated farther back than that represented in Text-fig. 12.

(2, p. 391, fig. 60) consists of a tooth rudiment which is older than those figured in the present paper, inasmuch as one germ is already bell-shaped, while the accompanying germ is racket-shaped like those which I figure on the preceding pages. On

the other hand the small anterior outgrowth, characteristic of so many of the teeth of the upper jaw in *Physeter*, may perhaps have been missed owing to its non-occurrence in the sections actually figured by Kükenthal. Or the pyramidal outgrowth may have been missed for similar reasons, as suggested above on general grounds. If this be so, then the teeth of *Physeter* will come more into line with those of other Cetacea, and be less abnormal than the facts described and illustrated here would imply. But again it is as likely—perhaps more likely—that the figure of Kükenthal is to be compared rather with the lower jaw teeth of *Physeter*.

Finally, the fact is to be emphasized that these more basally situated outgrowths of a more or less pyramidal form are only to be found among the teeth which are in the anterior part of the upper jaw; and it is only farther back that the long filiform outgrowth is to be seen. There is thus a differentiation of the upper jaw teeth into an anterior and a posterior series, which is remarkable.

#### COMPARISON OF TEETH OF LOWER AND UPPER JAW.

Having now dealt with the structure of the teeth of the upper jaw, we are in a position to compare them more accurately with those of the lower jaw. There is, I think, on the whole, reason for believing that there are differences between these two series. It is remarkable, however, that Pouchet and Beauregard figure no differences between teeth of the upper and lower jaw in their memoir. Such differences as I shall point out, or recall from the above references, from the teeth of the lower jaw, may be therefore merely a matter of age. Whether this be the case or not, the younger foetus shows the following apparent differences between the two series of teeth—those of the upper and those of the lower jaw. Apart from size, and shortness of the dental lamina in the teeth of the lower jaw, the chief—and indeed perhaps the only—difference between the two series lies in the fact that whereas the dental lamina has only one outgrowth in addition to that which forms the persistent tooth in the case of the teeth of the lower jaw, there are at

least and generally two such outgrowths in the teeth of the upper jaw. The most anterior of these (i. e. that closest to the persisting tooth rudiment) is to be regarded as the residual lamina which is alone (?) met with in the teeth of the lower jaw. Whether I am right or not in regarding the second outgrowth as a milk rudiment, it is at least a point of difference between these teeth and those of the lower jaw, where it appears to be non-existent—at any rate in the embryo which I have examined.

This again may be a matter of age. As to the residual lamina its exact likeness to that of the lower teeth is not absolute. There is this important difference. While in the case of the lower teeth the lamina is a lamina continuous from section to section, it is not so with the upper teeth; here in fact the small process (see Text-fig. 10) which may be its equivalent disappears and reappears every two or three sections, thus indicating a series of processes and not a continuous lamina (cf. Text-figs. 9, 10). There is next to be seen a difference—perhaps more apparent than real—between the mode of origin of what I regard as the permanent tooth in the upper and lower jaws.

As has been already mentioned, the tooth germ in both arises as a thickening of the end of the dental lamina, which is continuous as a thickened edge to that lamina. In examining the whole series of teeth rudiments in the lower jaw, from their commencement at the condylar end of the jaw, the following stages may be detected. The oval thickening, shown in Text-fig. 5, persists in section after section, but gradually alters its shape to a more triangular outline, and at the pointed end away from the origin of the dental lamina the residual lamina gets gradually to be free, the rest of the thickening remaining behind, so to speak, as the actual tooth germ.

In the upper jaw the series of events is rather different. The same thickened edge appears at first, but its stalk grows longer until a racket-like structure is produced, as shown in Text-fig. 6. Instead of remaining as it is—as is the case with the lower jaw teeth—it is bent over lingually, and the residual



lamina appears as a new structure. There is, so to speak, no freeing of the residual lamina from the compound mass. Strictly speaking, therefore, there is not an exact homology between the concave surfaces of the future cup-shaped enamel cap in the two series of teeth. It is terminal in one and lateral in the other.

But it must be remembered that, as I have pointed out above, the more mature teeth, i. e. those at the symphysis end of the jaw, apparently approach the teeth of the upper jaw in this last-mentioned characteristic. The tooth germ, that is to say, is more elongated and oval. But what we are dealing with here is not the form of the growing tooth germ but its mode of origin. This is undoubtedly different in the teeth of the two jaws, as has been emphasized. But this latter consideration may be regarded perhaps as suggesting comparisons between the teeth of the two jaws which have not yet been closely examined. On the views just advanced the one outgrowth of the dental lamina beside the outgrowth which results in the tooth of the adult is a residual lamina. Its form, moreover, is highly suggestive of such an interpretation as is to be seen in Text-figs. 1 and 4; and I have put forward other facts. On the other hand, in the more mature teeth of the lower jaw the shape of the whole tooth germ is not unlike that of the Beluga as figured by Kükenthal, as pointed out on another page, and is of course also like that of the upper jaw of the present species and specimen represented in Text-fig. 10 of the present paper. Are there, in fact, after all, reasons for regarding the process which I have lettered 'c' in the teeth of the lower jaw (Text-fig. 4) as really the equivalent of the process lettered 'a' in the teeth of the upper jaw (e. g. Text-figs. 9, 10)?

If this is so, it is clear that a different view may have to be taken of the homologies of the two teeth rudiments than that advanced in the present paper.

For if the labial outgrowth immediately following the lingual outgrowth is a tooth germ, and not a residual lamina, it would appear to follow that it is this which is the rudiment of the tooth of the permanent dentition; and therefore that the tooth

which actually arrives at maturity is in reality of the milk dentition—a view which is held of the cetacean teeth. But to support this view requires some ‘manipulation’ of the facts set forth in the above pages, and in the memoir of Messrs. Pouchet and Beauregard. It is true that the labial process in the lower jaw teeth at the symphysis extremity of the jaws is very like the tooth rudiments of Beluga, and in fact many mammals, a likeness which is increased by the fact that this outgrowth does not form a continuous lamina as does its supposed homologue in earlier sections (i. e. at the condylar end of the jaw), but decreases in successive sections and seems to disappear. This, however, need only remind us of the residual lamina (as I regard it) in the upper jaw (see Text-figs. 9, 10), which is not a continuous lamina but a series of outgrowths.

A stronger argument in favour of the view advanced here is that on the hypothesis now being considered we should have to pay no attention at all to the conspicuous outgrowths of the upper jaw, which are difficult to explain away as of no importance and without meaning. But even then, it will be noted, we are left with an undoubted difference between the teeth of the two jaws, lower and upper, which is evident in other characteristics of these organs, and which is set forth in the present section of this paper.

#### PECULIARITIES OF TEETH OF PHYSETER AND COM- PARISON WITH THOSE OF OTHER MAMMALS.

It is possible to deduce from the foregoing pages such a comparison, which does not, however, shed a great deal of light upon the zoological relationships of the Cetacea, except perhaps in one of the points raised.

It is clear, at any rate, that *Physeter* agrees with other mammals in having the usual two dentitions and—as in many cases—a residual lamina containing the promise or possibility of a third dentition, sometimes abnormally developed farther (e. g. in man). Furthermore, I have shown reasons for believing that the permanent dentition, in this cetacean at least, is

preceded by a milk dentition, thus conforming to the generally accepted view that (as far at any rate as the facts contained in the present paper allow of a statement) the Cetacea are the offspring of a stock already provided with the typical Eutherian dentition.

Messrs. Pouchet and Beaugard, as has been duly pointed out in the above pages, register an apparent peculiarity of the developing teeth of *Physeter* in the form of tufts of outgrowths from either the dental lamina or as a direct series of buds arising—not from, but beside, the dental lamina. These I have not been able to discover in the younger foetus described by myself. But in any case they are not, as I believe, to be regarded as a peculiarity of *Physeter* or of the Cetacea. For others have dealt with structures which are, I think, essentially similar.

Thus Leche (3, Pl. ix, fig. 70; Pl. xi, figs. 64, 90; Pl. xvi, figs. 140–2) figures and refers to a number of small ‘tags’ attached to the dental lamina in *Phoca groenlandica*, in the bat *Phyllostoma*, and in the marsupial *Phascolarctus*. The latter figures are copied by Wilson and Hill (7, Pl. xxxi, figs. 76, 77). How far such outgrowths have anything to do with tooth formation—phylogenetically for instance—the facts at my disposal do not allow of a guess. They suggest themselves as a mere state of perhaps abnormal activity.

There is a final matter, however, in which a possibly important difference from that generally observed in mammals is to be seen in the developing teeth of *Physeter macrocephalus*. This concerns the continuation along the jaw not only of the dental lamina but of the actual tooth germs of the permanent series only. The more usual state of affairs in mammals must be referred to first. Thus in the earliest stage (Stage II) of the embryos of *Perameles* studied by them Messrs. Wilson and Hill (7, Pl. xxv, figs. 1, 2, and woodcut fig. 1 on p. 475) represent the origin of a third deciduous incisor which grows out of the dental lamina. In the first of these sections the dental lamina is shown alone without a trace of the tooth which

appears suddenly in the next sections as an outgrowth of the dental lamina. There is no trace of any direct connexion—additional to the dental lamina—between the germ of this tooth and preceding teeth; its enamel organ is a separate outgrowth of the dental lamina. In the same way these authors represent the growth of a premolar in the same animal in a later stage (Stage III).

There are seven sections figured (A-G), each three sections apart. It is not quite clear what is the exact connexion between the second premolar (represented in figs. A and B) and the dental lamina; but in any case the latter is shown as such (i. e. without any tooth outgrowths) in figs. C-F. Then in G suddenly appears—as an outgrowth of the dental lamina—the rudiment of deciduous premolar three; the whole tooth germ—that is, the actual tooth, the dental lamina, and the residual dental lamina, extending beyond the tooth—possessing a close resemblance to one of the teeth of the lower jaw in *Physeter*, such as is represented in Text-fig. 1 of the present paper. There is no trace here either of any continuous lamina connecting the individual tooth germs. A final instance is shown by Woodward in a reconstruction of the teeth, deciduous as well as permanent, of *Sorex* (10, Pl. xxv, fig. 19). In this figure the teeth are seen to depend from the dental lamina only, and to be completely separate from each succeeding and preceding tooth. Quite different is the state of affairs shown in my sections of *Physeter*. The processes of the dental lamina which I have identified above with the milk dentition are in fact a series of processes only arising at intervals from the dental lamina. But the permanent teeth are produced at the free end of the dental lamina (in the case of the upper jaw) or from its lingual surface, leaving a continuous residual lamina (in the case of the lower jaw). In the upper jaw the position of the future teeth is shown by a bending inwards of the entire dental lamina (see Text-figs. 6-8), and a thickening of the same at intervals; but there is no projection of the rudiments of teeth beyond the edge of the dental lamina, which is continuous between the successive teeth and is only different in

the interdental regions by its less swollen character. Precisely the same is to be seen in the lower jaw, where (Text-figs. 2-4) the dental rudiments are definite outgrowths of the dental lamina, which is, however, a continuous outgrowth, being merely thinner in the interdental intervals (Text-figs. 2, 3). This will, I think, be made plain by an inspection of the figures referred to. There is to be seen, as I interpret the facts ascertained and figured by Messrs. Wilson and Hill (8, p. 141, Text-fig. 1), a perhaps comparable state of affairs in the developing teeth of *Ornithorhynchus*.

In the younger of two foetuses examined by those two anatomists the entire dental lamina of both upper and lower jaw (of one side) is figured and described. From those figures and the descriptions it is to be inferred that the enamel organs of two teeth are differentiated in the substance of the lamina of each half-jaw as a thickening of it, and not as an outgrowth therefrom—the connecting part of the dental lamina remaining unaltered between those rudiments. This is, as I think, to be compared exactly with any two succeeding teeth of the upper jaw of *Physeter*, where the tooth thickening is merely the lamina itself, and the unaltered lamina remains in the same way between successive tooth germs. This—as it will not be forgotten—is different from the lower jaw teeth of *Physeter*; for these are outgrowths of the dental lamina in the form of a continued laminal outgrowth thickened at intervals to form the actual teeth rudiments, which remain connected by the unaltered laminal outgrowth.

The fusion between successive teeth in this the youngest stage of *Physeter* as yet known may have some bearing upon the theory of tooth origin, i. e. as to whether separate teeth, like those of *Physeter*, are primitive, or show signs of the breaking up of a complex tooth series. Are the unions between the individual teeth a promise of a later concretion, or the remains of a separation of the cusps of a complex tooth? I have not, however, been able to ascertain any further facts which bear upon this most interesting topic. I can, for example, see no gaps which might mark the boundaries of pre-existent

multicuspidate teeth, or, on the other hand, show by this arrangement the specialization of sets of separate cusps—a promise of separate multicuspidate teeth in the future. I may remark, however, that these connexions between successive teeth may possibly be related to the fact that in the adult the individual teeth are connected by a tough gum which comes away with them when they are forcibly removed from the bony trough in which they lie.

#### RÉSUMÉ.

As to the facts contained in the above pages they are really summed up in the illustrations which accompany the letterpress.

There are tooth germs from end to end of both upper and lower jaws, except at the posterior end of the series, where the dental lamina is not specialized in the upper jaw for some little distance. The teeth, in fact, are developed from behind forwards.

The dental lamina extends into the subjacent mesoderm at absolutely right angles to the horizontal plane of the head. The dentine papilla is represented only by a condensation of nuclei in the mesoderm; it does not yet extend into the cavity surrounding the enamel organ.

The tooth rudiments of the lower jaw are borne upon a shorter dental lamina than those of the upper jaw. They consist of the dental lamina which is prolonged beyond the tooth germ as a 'residual lamina' and of the tooth germ arising from the lingual surface of the lamina.

The tooth rudiments of the upper jaw are borne upon a longer dental lamina than those of the lower jaw. They consist of the dental lamina which is prolonged beyond the tooth germ as a 'residual lamina'; but this consists, not of a continuous lamina as in the lower jaw, but of a series of processes one to each of the successive tooth germs. In addition to these there is always a second outgrowth of the dental lamina on the labial side (sometimes doubled) lying nearer to the origin of the dental lamina, which do not form a continuous lamina but are separate outgrowths corresponding

each (or each two) to a tooth germ. In the anterior half of the jaw the tooth rudiments also possess two labial outgrowths, of which the first, i. e. that nearest to the tooth germ, is longer than in the posterior series of tooth germs, while the second, i. e. that nearest to the origin of the dental lamina, arises partly from the dental lamina and partly from the oesophageal epithelium, and forms a short pyramidal process. I have not seen intermediate conditions.

There is also a differentiation into two series of the teeth of the lower jaw, but the anterior teeth seem to differ merely through greater age.

In both the teeth of the upper and of the lower jaws the permanent tooth rudiments (i. e. those outgrowths from, and on the lingual side of, the dental lamina) are not isolated outgrowths of the dental lamina but are connected successively by a continuous outgrowth of the dental lamina, as follows :

In both lower and upper teeth the individual tooth germs arise from a marginal thickening of the dental lamina, but the subsequent course of the development differs in the two series. In the teeth of the lower jaw the thickening is shifted to the lingual side of the dental lamina by the freeing from it of a residual lamina on the labial side. In the upper jaw the corresponding thickening at the distal edge of the dental lamina is bent over to the lingual side, while a later formed residual lamina continues at intervals the straight line of the dental lamina ; thus the tooth germ has grown to lie laterally instead of being formed in situ.

As to the homologies of the various regions of the embryonic teeth, it has been attempted to show that there are reasons for believing that the teeth of the adult correspond to the permanent dentition of other mammals, that there are also rudiments of precedent milk dentition, and that a residual lamina succeeds the rudiments of the permanent dentition.

## LITERATURE.

1. Beddard.—“ Further Contributions to the Anatomy of the Sperm Whale (*Physeter macrocephalus*) based upon an Examination of two additional Foetuses ”, ‘ Ann. Durban Mus. ’, ii (part iv), 1919.
2. Kükenthal.—“ Walthiere ” in ‘ Denkseh. nat. Ges. Jena ’, Th. ii, 1893.
3. Leche.—“ Entwicklungsgeschichte des Zahnsystems der Säugethiere ”, ‘ Bibl. Zool. ’, vi, 1895, Heft 17.
4. Pouchet et Beauregard.—“ Recherches sur le Cachalot ”, ‘ Nouv. Arch. Mus. ’ (3) i, 1889.
5. Ritchie and Edwards.—“ On the Occurrence of Functional Teeth in the Upper Jaw of the Sperm Whale ”, ‘ Proc. Roy. Soc. Edin. ’, xxxiii, 1913, p. 166.
6. Tomes.—‘ Dental Anatomy ’, 6th ed., 1904.
7. Wilson and Hill.—“ Observations upon the Development of the Teeth in *Perameles*, &c.”, ‘ Quart. Journ. Micr. Sci. ’ (n.s.), xxxix.
8. ——— “ Observations on Tooth Development in *Ornithorhynchus* ”, *ibid.*, li.
9. Woodward, Martin.—“ Contributions to the Study of Mammalian Dentition, Part I ”, ‘ Proc. Zool. Soc. ’, 1893, p. 450.
10. ——— “ Contributions to the Study of Mammalian Dentition, Part II ”, *ibid.*, 1896, p. 557.